

CLINICAL QUIZ

## Splenic Hilar Mass With Pain, Diarrhoea and Sweating: Can It Be Malignant?

HAMIZI MH<sup>1</sup>, SANDRASECRA S<sup>2</sup>, HAYATI F<sup>3</sup>, AZIZAN N<sup>4</sup>,  
MAHAMAD DOM SA<sup>5</sup>, CHUAH JA<sup>2</sup>

<sup>1</sup>Department of Surgery, International Islamic University Malaysia Medical Center, Kuantan, Pahang.

<sup>2</sup>Department of Surgery, Queen Elizabeth Hospital I, Ministry of Health Malaysia, Kota Kinabalu, Sabah, Malaysia.

<sup>3</sup>Department of Surgery, Faculty of Medicine and Health Sciences, Universiti Malaysia Sabah, Sabah, Malaysia.

<sup>4</sup>Department of Pathobiology and Medical Diagnostic, Faculty of Medicine and Health Sciences, Universiti Malaysia Sabah, Sabah, Malaysia.

<sup>5</sup>Department of Pathology, Queen Elizabeth Hospital I, Ministry of health Malaysia, Kota Kinabalu, Sabah, Malaysia.

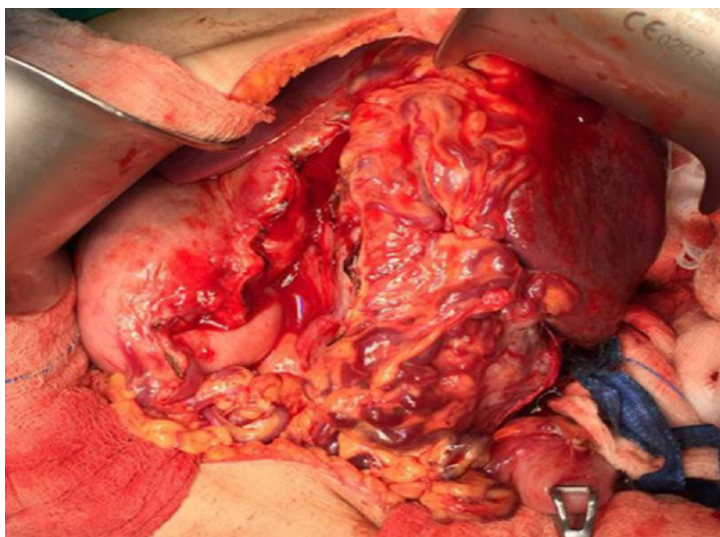


Figure 1: A hard nodular mass at the hilum of spleen with dilated tortuous vessel

**Address for correspondence and reprint requests:** Firdaus Hayati. Department of Surgery, Faculty of Medicine and Health Sciences, Universiti Malaysia Sabah, Kota Kinabalu, Sabah, Malaysia. Tel: +088-320000 ext. 611029 E-mail: [firdaushayati@gmail.com](mailto:firdaushayati@gmail.com)

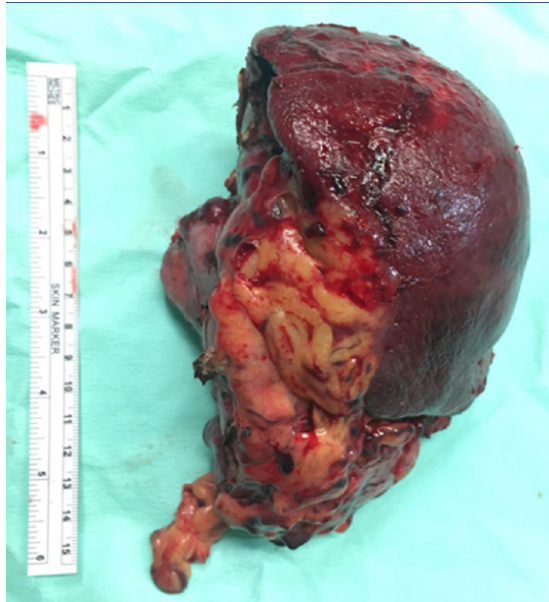

Figure 2: Macroscopic picture of splenectomy and distal pancreatectomy specimen

### QUESTION

A 37-year-old lady with no known comorbidity complained of left hypochondrial pain for 6 months duration. It was associated with loss of weight and appetite with occasional carcinoid symptoms such as diarrhoea and sweating. She had no blood transfusion before. Clinically, she has no features of thalassemia and the abdomen was soft with a palpable vague mass on the left hypochondrial region. A computed tomography (CT) of the abdomen revealed a soft tissue mass measuring 8.9 x 10.3 x 9.0 cm in the enlarged spleen. A laparotomy was decided and the intraoperative findings are as in Figure 1 and 2. Spot the diagnosis and provide the outline of management.