

Functional Outcome of Hindfoot Arthrodesis in Charcot Arthropathy

KUHARAJAN R, MOHD YAZID B, OHNMAR H,
YULIAWIRATMAN BS

Department of Orthopaedics and Traumatology, Faculty of Medicine, Universiti Kebangsaan Malaysia Medical Centre, Jalan Yaacob Latif, Bandar Tun Razak, 56000 Cheras, Kuala Lumpur, Malaysia

ABSTRAK

Charcot Arthropathy adalah keadaan degeneratif yang menjejaskan satu atau lebih sendi yang ditandakan oleh ketidakstabilan sendi dan hipermobiliti hasil daripada kerosakan saraf periferi. Kajian ini adalah kajian retrospektif yang dilakukan pada pesakit yang didiagnosis dengan Charcot Arthropathy dan menjalani pembedahan untuk artrodesis hindfoot di Hospital Universiti Kebangsaan Malaysia, dari Januari 2011 hingga Jun 2016. Tujuan kajian ini adalah untuk mengkaji kemungkinan kebolehlaksanaan algoritma dalam menguruskan Charcot Arthropathy dan menilai hasil fungsi, klinikal dan radiografi daripada sendi Charcot yang dirawat dengan arthrodesis hindfoot, sekurang-kurangnya 6 bulan susulan dengan menggunakan sistem pemarkahan piawai dan antarabangsa, iaitu Skor American Orthopaedic Foot and Ankle Surgery (AOFAS) dan SF36. Daripada 16 pesakit yang direkrut dalam kajian ini, 4 (25%) adalah lelaki dan 12 (75%) adalah pesakit wanita. Umur minima adalah 58.1 (20-71) tahun. Terdapat distribusi yang sama untuk bahagian cantuman. Sebanyak 13 dari 16 kes (81%) kami yang disusuli telah mendapati tulang bercantum. Dari 3 pesakit yang tulangnya tidak bercantum, 2 disebabkan oleh jangkitan yang mendalam. Skor AOFAS untuk hindfoot dan midfoot menunjukkan peningkatan baik selepas operasi dengan nilai $p < 0.05$ dan skor mental SF36 dengan nilai $p < 0.05$. Komponen Fizikal SF36 tidak menunjukkan peningkatan statistik. Algoritma rawatan yang kini digunakan di pusat kami boleh diterima dan menunjukkan hasil yang baik. Walaupun hasilnya adalah dalam kadar yang boleh diterima, usaha kini harus memberi tumpuan kepada mengurangkan komplikasi sebagai beban jangkitan dan bukan kesatuan yang masih menjadi komplikasi yang diketahui bagi kebanyakan pembedahan yang berkaitan dengan tulang.

Kata kunci: artropati, cantum, charcot, kaki-belakang

Address for correspondence and reprint requests: Assoc. Prof. Dr. Mohd Yazid Bajuri. Department of Orthopaedics and Traumatology, Faculty of Medicine, Universiti Kebangsaan Malaysia Medical Centre, Jalan Yaacob Latif, Bandar Tun Razak, 56000 Cheras, Kuala Lumpur, Malaysia. Tel: +6017 2771000 Email: ezeds007@yahoo.com.my

ABSTRACT

Charcot arthropathy is a devastating degenerative condition which affects one or more joints that is marked by joint instability, hypermobility resulted from peripheral nerve damage. This was a retrospective study performed on patients who were diagnosed with Charcot arthropathy and those underwent surgery for hindfoot arthrodesis at Universiti Kebangsaan Malaysia Medical Centre from January 2011 until June 2016. The objective of the study was to review the feasibility of an algorithm in managing Charcot arthropathy and to assess functional, clinical and radiographic outcomes of Charcot arthropathy joints treated with hindfoot arthrodesis, at least 6 months follow-up using standardized and internationally accepted scoring systems, which were the American Orthopaedic Foot and Ankle Surgery (AOFAS) score and SF36. A total of 16 patients were included in this study of which 4 (25%) were males and 12 (75%) were females. The mean age was 58.1 (20-71) years. There was equal distribution for side of fusion. We achieved union in 13 out of our 16 (81%) cases followed up. Out of the 3 patients with non-union, 2 were attributed to deep infections. The AOFAS scores for hindfoot and midfoot showed significant improvement post operatively with p-value <0.05 as well as the SF36 mental scores with p-value <0.05. The Physical Component of SF36 showed no improvement. The treatment algorithm currently used in our centre is acceptable and shows good outcomes. While the outcomes are of acceptable rates, efforts should now focus on reducing the complications as the burden of infection and non-union remains a known complication for most bone-related surgeries.

Keywords: arthropathy, charcot, fusion, hindfoot

INTRODUCTION

Charcot arthropathy is a devastating degenerative condition affecting one or more joints that is marked by joint instability and hypermobility resulted from peripheral nerve damage. It is a common complication seen in patients with diabetes mellitus as well as more uncommonly in those with spinal cord disorders.

There are few factors required for the arthropathy to occur and these include peripheral neuropathy, unrecognized

injury, continuous stress on injury and an increased local blood flow as described by Rosenbaum et al. 2014. Based on Eichenholtz classification, stage 0 and 1 with clinical findings including swelling, erythema and warmth, the current management is aimed towards protected weight bearing or offloading. This is achieved by crutches or total contact casting. In stage 2, the clinical findings are reduced, and radiologically there is sclerosis, fusion of larger fragments, with resorption of debris. In this stage,

total contact casting is still advocated, with CROW (Charcot restraint orthotic walker) a suitable substitute. Stage 3, which is the area of interest in our study, shows consolidation of the deformities. There is minimal inflammation at this stage, making surgery a good option for management. Surgical options in the absence of ulceration and infection, include deformity correction or joint fusion utilizing internal or external fixation depending on the deformity (Rosenbaum et al. 2014).

With increasing incidences of diabetic related foot complications such as neuropathy, ischemic foot ulcers, osteomyelitis especially in long standing diabetics, a treatment algorithm would be beneficial in managing these complex cases. Siebachmeyer et al. 2015 described an algorithm which is widely use in treating Charcot arthropathy as shown in Figure 1 (Siebachmeyer et al. 2015). We describe an algorithm which include a pharmacological treatment

for management of Diabetic Charcot arthropathy as shown in Figure 2. There are various options for managing these diabetic foot problems, basically from wound debridement to amputation in more severe cases. Surgery is considered for patients with Charcot arthropathy with residual foot deformities. Depending on the areas of involvement, surgical fusion options include external fixation, which is either multi or uni-planar, internal fixation with nails or plates and screws. A study by Shah & De described that a nail fusion has less complications compared to external fixators (Shah & De 2011).

However, there are still some controversies in managing complicated cases. Monitoring of surgical outcome is the utmost important for treating surgeons to improve their management plans and assist with decision making. Thus, we decided to conduct this study on treatment algorithm and functional outcome of hindfoot arthrodesis in

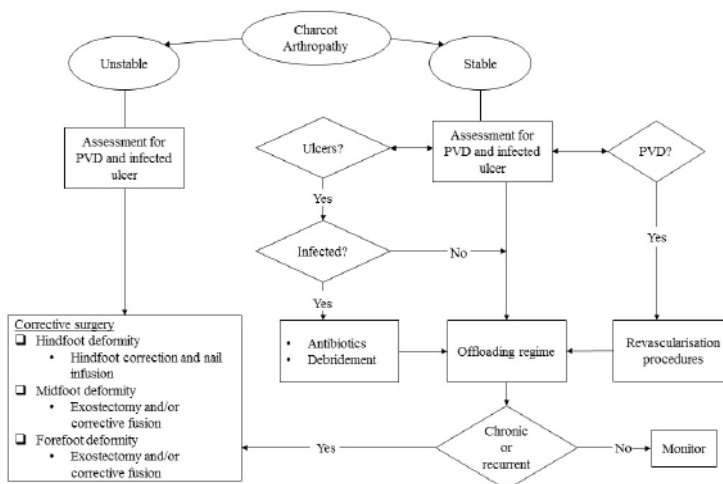


Figure 1: Management algorithm for patients with Charcot foot deformity. Offloading regime comprises using total contact cast, pneumatic cast and foot and ankle orthotic (PVD, peripheral vascular disease)

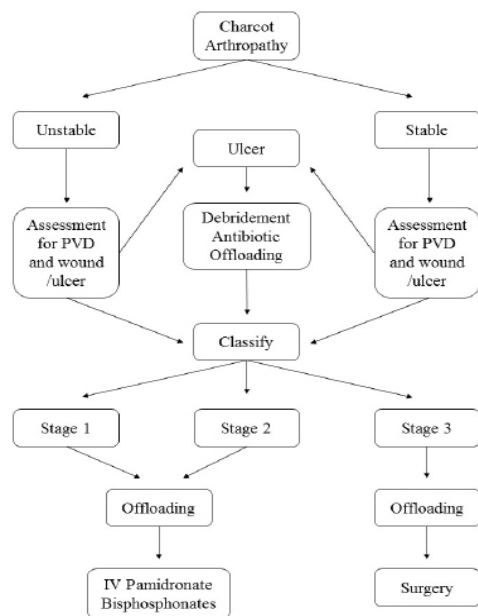


Figure 2: Management algorithm for patients with Charcot foot deformity used in this study

Charcot Arthropathy in Universiti Kebangsaan Malaysia Medical Centre.

The objective of the study was to review the feasibility of an algorithm in managing Charcot arthropathy and to assess functional, clinical and radiographic outcome of Charcot joints treated with hindfoot arthrodesis, of at least 6 months follow-up using standardized and internationally accepted scoring systems which are the American Orthopaedic Foot and Ankle Surgery (AOFAS) score, Short Form Survey Instrument (SF36) and radiographic assessment of foot and ankle.

MATERIALS AND METHODS

The study was approved by Research Ethics Committee from The National University of Malaysia (UKM PPI/111/8/

JEP-2016-437). The scoring for AOFAS and SF36 was done retrospectively, and the radiographs of the patients reviewed on follow up. Patients whose follow-up were not convenient, were contacted by telephone.

This was a retrospective study done in patients who were diagnosed with Charcot arthropathy and underwent surgery for hindfoot arthrodesis at the Universiti Kebangsaan Malaysia Medical Centre, from January 2011 until June 2016. Hindfoot arthrodesis surgery is the surgical fusion of the ankle and subtalar joints.

Patients with Charcot Arthropathy (according to Eichenholtz classification) treated with arthrodesis at least 6 months follow-up aged 18 and above were included in this study. Patients with medical conditions or trauma, which caused debilitating symptoms such as non-related fractures and cerebral vascular accidents were not included in this study. Patient defaulted from follow-up or unable to contact during study and aged below 18 years, were also not included in this study.

Functional status and health status were assessed using American Orthopaedic Foot and Ankle Society score, Short-Form 36 & radiographic evaluation. The Short Form (36) Health Survey is a survey of patient's health. The SF-36 consists of eight scaled scores, which are the weighted sums of the questions in their section. Each scale is directly transformed into a 0-100 scale on the assumption that each question carries equal weight. The validity and reliability have been widely studied and reported. It is also used in various studies done worldwide.

Table 1: Statistical analysis using Paired T-Test where significant value is p<0.05

		Paired Differences					t	df	Sig. (2-tailed)
		Mean	Std. Deviation	Std. Error Mean	95% Confidence Interval of the Difference				
					Lower	Upper			
Pair 1	AOFAS Hindfoot Pre AOFAS Hindfoot Post	-29.000	22.048	5.512	-40.749	-17.251	-5.261	15	.000
Pair 2	AOFAS Midfoot Pre AOFAS Midfoot Post	-28.3750	22.7329	5.6832	-40.4885	-16.2615	-4.993	15	.000
Pair 3	SF36 Physical Pre SF36 Physical Post	-2.88875	9.59896	2.39974	-8.00367	2.22617	-1.204	15	.247
Pair 4	SF36 Mental State Pre SF36 Mental State Post	-9.44437	9.09594	2.27399	-14.29126	-4.59749	-4.153	15	.001

The eight sections are vitality, physical functioning, bodily pain, general health perceptions, physical role functioning, emotional role functioning, social role functioning and mental health.

The AOFAS has 4 modules of assessment which are 1st MPJ & ray, forefoot, rear and midfoot (used in study) and ankle. These areas are then divided in to a subjective and objective scoring system. The subjective aspect assessed are pain, appearance and function, while objective assessment included radiological and functional tests.

Radiographic evaluation aims to review the union of the arthrodesis as well as any evidence of infection including implant related. The evaluation was performed by a single orthopaedic ankle and foot consultant.

For the ethical issues in this study,

patients and family members are informed that their records and images would be reviewed for research purposes and they are granted the opportunity to forbid such use of their data.

RESULTS

Upon reviewing the operative registry at Universiti Kebangsaan Malaysia

Table 2: Demographic distribution

Demography	Number (n)	
Male	4	25%
Female	12	75
Mean age (years)	58.1	(20-71)
Left	8	50%
Right	8	50%
Eichenholtz Stage III	16	100%
Diabetic	13	81.2%

Table 3: List of complications

Complications	Number (n)	Percentage
Non-union	3	19%
Deep infection with loosening of screw	2	12.5%
Deep infection with removal of implant	3	19%
Superficial infection with loosening of screw	1	6%
Superficial infection	1	6%
Aseptic loosening of screw	1	6%

Medical Centre, a total of 64 hind foot fusions were done between January 2011 until June 2016. The treatment algorithm that we used in this study was illustrated in Figure 2. From this total, upon reviewing case and operative notes, a total of 24 cases were diagnosed cases of Charcot arthropathy. A total of 6 patients were not contactable, 1 declined and 1 other patient passed away due to complications arising out of diabetes. The remaining 16 were included in the study.

Data was analysed using commercially available software SPSS version 22.0 for Windows at the

significant level $p < 0.05$ (Table 1).

The number of male patients were 4 (25%) compared to 12 (75%) female patients (Table 2). The mean age was 58.1 years (20-71). The side of fusion was equal for both right and left (8/ side). All patients reviewed were in Eichenholtz stage III during the timing of surgery. A total of 13 of the patients were diabetics, 2 had spina bifida and one patient had end stage renal failure.

An 81% union rate was achieved in our patients, but 3 patients had non-union. Out of the 3 patients with non-union, 2 were attributed to deep infections (Table 3). There were also 2 cases of deep infection requiring

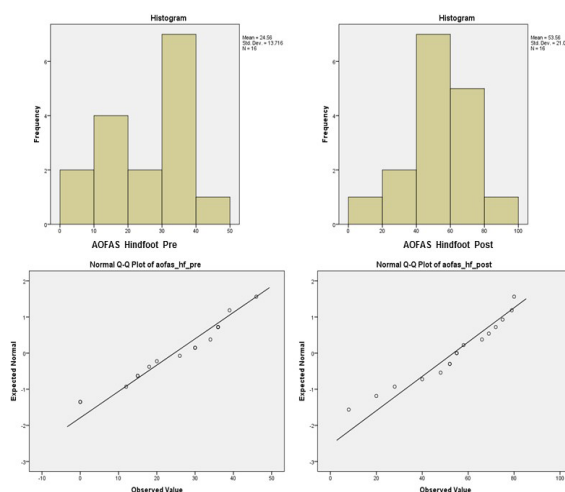


Figure 3: Distribution of mean scores of AOFAS Hindfoot (pre and post)

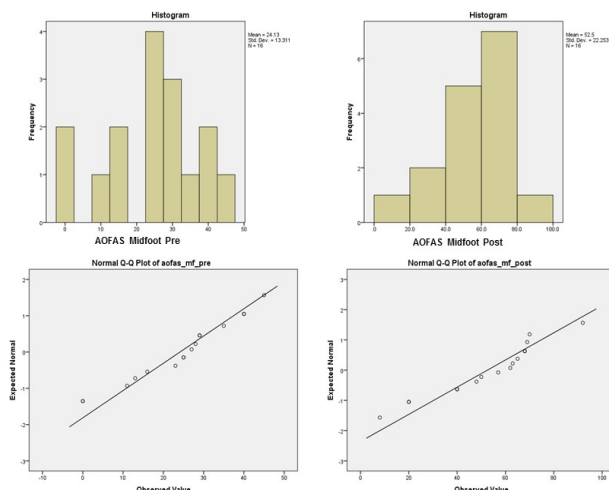


Figure 4: Distribution of mean scores of AOFAS midfoot (pre and post)

removal of screw, as well as one case each of aseptic loosening of screws, superficial surgical site infection, and deep surgical infection. However, union was achieved in these patients. As the AOFAS and SF36 results were normally distributed, the paired T-test was used. The AOFAS (hindfoot) mean was 24.56 for pre- and 53.56 for post-operatively (Figure 3). The AOFAS (midfoot) showed similar

results with 24.13 for pre- and 52.50 for post-operatively (Figure 4). The SF36 (mental) reported a significant improvement with p-value <0.05 in the mean scores 40.46 pre- and 49.91 post-operatively (Figure 5), while the SF36 (physical) reported no significant changes in pre-and post-operative period (35.11 & 38.04) (Figure 6).

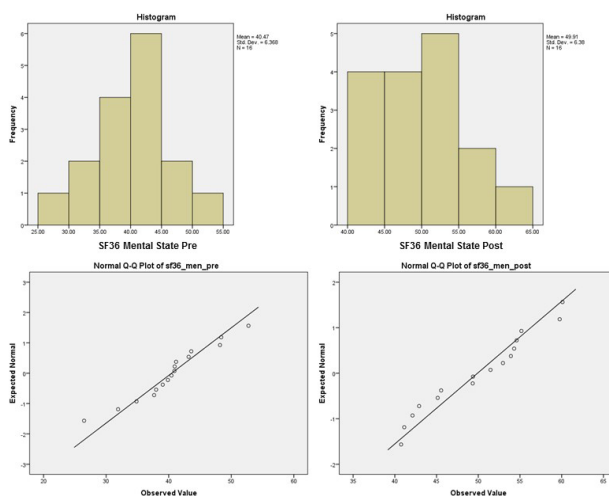


Figure 5: Distribution of mean scores of SF36 mental (pre and post)

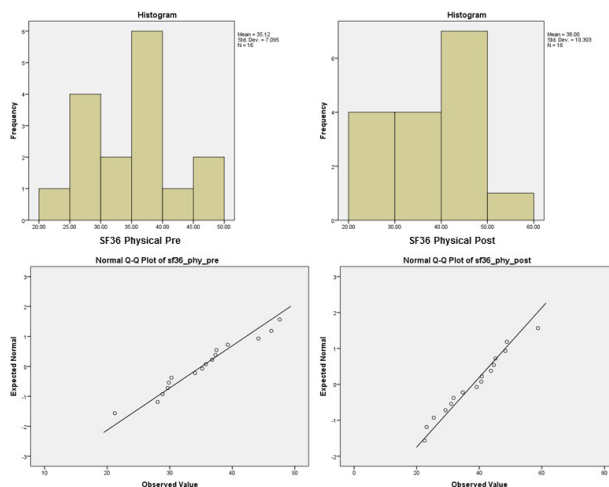


Figure 6: Distribution of mean scores of SF36 physical (pre and post)

DISCUSSION

Charcot Neuroarthropathy (CN) has been attributed to an insensate limb. There are two postulated theories, which are neurovascular insufficiency and neurotraumatic. The former implies that the loss of autonomic supply results in an increased blood supply to the region, therefore increasing bone resorption. The latter suggests that a repetitive insult to the insensate limb causes microfracture. There is joint, soft tissue and bone inflammation with loss of architecture, which inevitably leads to instability, loss of joint congruency and bony destruction (Rajbhandari et al. 2002; Rogers et al. 2011; Kaynak et al. 2013). The diagnosis of this disease requires a high index of suspicion and a being able to identify neurological, vascular, and radiographic pathologies. Differentials to be considered are gout, deep vein thrombosis, rheumatoid arthritis and infections (Güven et al. 2013; Game et al. 2011).

The management of CN should

be divided into acute and chronic. Acute management in the early stages should focus on reduce the destructive properties of the disease. This is achieved by a non-weight bearing protocol or offloading with a total contact cast. The role of bisphosphonates is controversial with no long-term studies available yet to justify the use. The management of chronic CN aims to get a stable, plantigrade, painless, shoe able foot with avoidance of ulcer formation (Rajbhandari et al 2002; Rogers et al. 2011; Güven et al. 2013; Mittlmeier et al. 2009). Restoration of quality of life is important, as patients with CN are found to have a reduced level of physical activity when compared to more severe ailments (Mittlmeier et al. 2009). A study has shown that hyperbaric oxygen therapy can act as an adjunctive therapy to improve wound healing and at the same time helps to achieve a better quality of life especially in chronic diabetic foot ulcer (Bajuri et al. 2017).

Orthosis and surgical intervention are indicated, with arthrodesis with internal, external or combined fixations, exostectomies and reconstruction all options to achieve good outcomes. There is a report noted that complex reconstruction needs a bone graft as part of the fixation in order to maintain the structure of the reconstructed part. This helps the ossification to occur and later consolidation will take place (Muhammad Hafiz et al. 2018). Union rates for ankle and hindfoot arthrodesis are between 80-99% (Siebachmeyer et al. 2015; Zwipp et al. 2009) and this is despite the risk factors of vascular insufficiency and reduced immune status of patients. Limb amputation is reserved as the last resort (Güven et al. 2013).

The usage of intermedullary fixed angle device with bone graft provides a safe and rigid fixation for patient with CN. While this holds true for patient with relatively good bone stock, those with talus insufficiency, a talectomy along with tibiocalcaneum fusion will be a good option (Ahmad & Raikin 2008). We did not encounter this in our series of cases. The type of deformity dictates the correction required as well as site of correction. Malerba et al. (2015) report of no significant difference in both isolated tibiotalar and combined tibiotalar subtalar fusion. While isolated tibiotalar fusion does allow for some motion at the subtalar joint, there is associated morbidity of degenerative changes in this area (Malerba et al. 2015). Severe ankle and hindfoot conditions that cannot be adequately managed by other measures, can be treated using

hindfoot fusion which act as a salvage option that offers a safe and reliable treatment (Rammelt et al. 2013).

We proceeded for surgery when our patients were in the 3rd stage of CN as the inflammatory markers now were normal. Simon et al., however, report a good clinical outcome in patients who underwent arthrodesis in Eichenholtz stage I. There was no infection and all 14 patients achieved union, with mean return to use of regular shoe was 27 weeks (Simon et al. 2000).

Schneekloth et al. 2016 found out that there is no direct comparison between the performance of surgery in the acute phase versus surgery in chronic phase but there is an encouraging result in surgical intervention done during acute phase (Schneekloth et al. 2016).

While we utilized the anteromedial and lateral approaches, Pelligrini et al all reported a series of cases utilizing posterior Achilles Tendon-splitting approach with a union rate of 80%. However, the reported complications were significantly higher at 41% (Pellegrini et al. 2016).

Based on a report, Ilizarov external fixator (IEF) can be used as an alternative treatment in treating the subtalar dislocation with unstable foot. This will allow a progressive soft tissue correction and at the same time provides the stability for arthrodesis (Bajuri et al. 2013). Fragomen et al. reported an 73% union rate in their review of using IEF for complex ankle fusions with CN as compared to 84%, overall. Non-smokers and non-CN patients had a 93% fusion rate (Fragomen et al. 2012). While IEF offers

the advantage of earlier weight bearing, the authors delayed weight bearing in the CN group, worrying about failure of the construct. When comparing the hindfoot nail to a uniplanar fixation though, the complication rate was significantly higher in the uniplanar method as well as a reduced union rate in which 100% by using nail & 66.7% with external fixation (Shah & De 2011). Complications associated with the uniplanar external fixation include pin tract loosening, pin site infection, and wound breakdown.

Complications with arthrodesis with regards to infection vary from superficial surgical site infection (5-49%) to deep seated osteomyelitis (up to 9%) (Zwipp et al. 2009; Pellegrini et al. 2016; Fragomen et al. 2012; Eschler et al. 2015). The presence of the hindfoot nail also invites the risk of stress fractures to the lower limb. Mansor et al. hypothesized that the crack path relies on the bone matrix microstructure in which the fracture toughness will increase with mode mixity (Mansor et al. 2015). Lidor et al. recognized thirteen stress fractures in one hundred and five ankle arthrodesis (12.8%). While the fractures can be treated, it still represents a short-term morbidity to the patient (Lidor et al. 1997).

One of the limitations of the present study was the small sample size. Hence, studies with bigger sample size are advised in future.

CONCLUSION

The treatment algorithm currently used in our centre is acceptable and

shows good outcomes. While the outcomes are of acceptable rates, efforts should now focus on reducing the complications as the burden of infection and non-union remains a known complication for most bone-related surgery.

ACKNOWLEDGEMENT

The authors would like to thank Professor Dr. Srijit Das and Dr. Kamarul Syariza Zamri for their indirect contribution and technical help in publishing this manuscript.

REFERENCES

- Muhammad Hafiz, A.S., Mohd Yazid, B., Norliyana, M., Rasyidah, R. Limb salvage surgery in chronic osteomyelitis: a case report. *Med & Health* 13(1): 286-90.
- Ahmad, J., Raikin, S.M. 2008. Ankle Arthrodesis: The Simple and the Complex. *Foot and Ankle Clinics*. 13(3):381-400.
- Bajuri, M.Y., Abdullah, A. 2017. Ankle arthritis: which to choose – arthrodesis or arthroplasty. *Journal of Surgical Academia* 7(1): 4-8.
- Bajuri, M.Y., Abdullah, A., Nurhanani, A.B., Hassan, M.R. 2017. The physiological, biochemical and quality of life changes in chronic diabetic foot ulcer after hyperbaric oxygen therapy. *Med & Health* 12(2): 210-9.
- Bajuri, M.Y., Johan, R.R., Bahari, S.I. 2013. Neglected subtalar dislocation with unstable foot; to walk away or step our foot in?. *BMJ Case Reports* 2013(Jan 17): 1-4.
- Eschler, A., Gradl, G., Wussow, A., Mittlmeier, T. 2015. Prediction of complications in a high-risk cohort of patients undergoing corrective arthrodesis of late stage Charcot deformity based on the PEDIS score. *BMC Musculoskeletal Disord* 16: 349.
- Fragomen, A.T., Borst, E., Schachter, L., Lyman, S., Rozbruch, S.R. 2012. Complex ankle arthrodesis using the ilizarov method yields high rate of fusion. *Clin Orthop Relat Res* 470(10): 2864-73.
- Game, F.L., Catlow, R., Jones, G.R., Edmonds, M.E., Jude, E.B., Rayman, G., Jeffcoate, W.J. 2011. Audit of acute Charcot's disease in the UK: the CDUK study. *Diabetologia* 55(1): 32-5.
- Güven, M.F., Karabiber, A., Kaynak, G., Oğut, T.

2013. Conservative and surgical treatment of the chronic Charcot foot and ankle. *Diabetic Foot & Ankle* 4: 21177.
- Kaynak, G., Birsal, O., Fatih Güven, M., Ogut, T. 2013. An overview of the Charcot foot pathophysiology. *Diabet Foot Ankle* 4(1):21117.
- Lidor, C., Ferris, L.R., Hall, R., Alexander, I.J., Nunley, J.A. 1997. Stress fracture of the tibia after arthrodesis of the ankle or the hindfoot. *J Bone Joint Surg Am* 79(4): 558-64.
- Malerba, F., Benedetti, M.G., Usuelli, F.G., Milani, R., Berti, L., Champlon, C., Leardini, A. 2015. Functional and clinical assessment of two ankle arthrodesis techniques. *J Foot Ankle Surg* 54(3): 399-405.
- Mansor, N.N., Daud, R., Basaruddin, K.S., Omar YeYutt, M.I., Halim, S.A.A., Zain, N.A.M., Bajuri, M.Y. 2015. Review of biomechanical modelling of cortical bone stress fracture. 2015 *2nd International Conference On Biomedical Engineering (IcoBE)*.
- Mittlmeier, T., Klaue, K., Haar, P., Beck, M. 2009. Should one consider primary surgical reconstruction in charcot arthropathy of the feet? *Clin Orthop Relat Res* 468(4): 1002-11.
- Pellegrini, M.J., Schiff, A.P., Adams, S.B., DeOrio, J.K., Easley, M.E., Nunley, J.A. 2016. Outcomes of tibialocalcaneal arthrodesis through a posterior achilles tendon-splitting approach. *Foot Ankle Int* 37(3): 312-9.
- Rajbhandari, S.M., Jenkins, R.C., Davies, C., Tesfaye, S. 2002. Charcot neuroarthropathy in diabetes mellitus. *Diabetologia*. 45(8): 1085-96.
- Rammelt, S., Pirc, J., Ågren, P.H., Hartsock, L.A., Cronier, P., Friscia, D.A., Hansen, S.T., Schaser, K., Ljungqvist, J., Sands, A.K. 2013. Tibialocalcaneal fusion using the hindfoot arthrodesis nail. *Foot Ankle Int* 34(9): 1245-55.
- Rogers, L.C., Frykberg, R.G., Armstrong, D.G., Boulton, A.J., Edmonds, M., Van, G.H., Hartemann, A., Game, F., Jeffcoate, W., Jirkovska, A., Jude, E., Morbach, S., Morrison, W.B., Pinzur, M., Pitocco, D., Sanders, L., Wukich, D.K., Uccioli, L. 2011. The charcot foot in diabetes. *Diabetes Care*. 34(9): 2123-9.
- Rosenbaum, A.J., DiPreta, J.A. 2014. Classifications in brief: eichenholtz classification of charcot arthropathy. *Clin Orthop Relat Res* 473(3): 1168-71.
- Schneekloth, B.J., Lowery, N.J., Wukich, D.K. charcot neuroarthropathy in patients with diabetes: an updated systematic review of surgical management. *J Foot Ankle Surg* 55(3): 586-90.
- Shah, N.S., De, S.D. 2011. Comparative analysis of uniplanar external fixator and retrograde intramedullary nailing for ankle arthrodesis in diabetic Charcot's neuroarthropathy. *Indian J Orthop* 45(4): 359-64.
- Siebachmeyer, M., Boddu, K., Bilal, A., Hester, T.W., Hardwick, T., Fox, T.P., Edmonds, M., Kavarthapu, V. 2015. Outcome of one-stage correction of deformities of the ankle and hindfoot and fusion in Charcot neuroarthropathy using a retrograde intramedullary hindfoot arthrodesis nail. *Bone Joint J* 97-B(1): 76-82.
- Simon, S.R., Tejwani, S.G., Wilson, D.L., Santner, T.J., Denniston, N.L. 2000. Arthrodesis as an early alternative to nonoperative management of charcot arthropathy of the diabetic foot. *J Bone Joint Surg Am* 82(7): 939-50.
- Zwipp, H., Rammelt, S., Endres, T., Heineck, J. 2009. High union rates and function scores at midterm followup with ankle arthrodesis using a four screw technique. *Clin Orthop Relat Res* 468(4): 958-68.

Received: 7 Feb 2019

Accepted: 24 May 2019