

# External Marker in Bisecting-Angle-Technique: A New Approach to Minimize Dental Radiographic Error

AZIZAH AF, MUHAMAD AQIL AA, MOHD AMIRUL Z, ATIKA A

*Department of Clinical Oral Biology, Faculty of Dentistry, Universiti Kebangsaan Malaysia, Jalan Raja Muda Abdul Aziz, 50300 Kuala Lumpur, Malaysia.*

## ABSTRAK

*Teknik 'bisecting-angle' merupakan satu kaedah yang digunakan bagi menambah baik keselesaan pesakit semasa radiografi periapikal. Kebiasaannya, teknik ini dilakukan tanpa menggunakan alat sasaran sinar-X dan sering kali mengakibatkan ralat pada radiograf pergigian. Penggunaan penanda luaran sebagai alat bantuan bagi mensasarkan sinar-X di dalam teknik 'bisecting-angle' adalah berpotensi bagi mengurangkan ralat radiograf berkenaan. Dalam kajian ini, 240 radiograf periapikal diambil oleh pelajar sarjana muda pergigian dengan menggunakan 3 jenis teknik radiograf periapikal. Teknik-teknik ini adalah teknik 'bisecting-angle' (BAT), teknik 'bisecting-angle' dengan menggunakan penanda luaran (BAT-M) dan teknik 'paralleling' (PT). Setiap radiograf yang diambil, seterusnya dinilai dan ralat yang terdapat pada radiograf diklasifikasikan dan dijadualkan mengikut jenis dan bilangan ralat radiograf yang berlaku. Analisis statistik yang lebih terperinci turut dilakukan bagi membandingkan jumlah bilangan ralat radiograf yang melibatkan ketiga-tiga teknik berkenaan. Keputusan kajian menunjukkan salah satu ralat radiograf yang sering terjadi dengan BAT adalah ralat potongan kon (13.8%). Ralat ini didapati berkurangan kepada 1.3% dan 2.5% dengan pelaksanaan BAT-M dan PT, masing-masing. Jumlah keseluruhan ralat radiograf juga didapati jauh lebih kecil dengan BAT- M berbanding BAT,  $p < 0.05$ .*

*Kata kunci: ralat, pergigian, radiografi*

## ABSTRACT

Bisecting-angle-technique is a method used to improve patient comfort during periapical radiography. This technique is usually performed without X-ray beam aiming device and has been commonly associated with dental radiographic error.

**Address for correspondence and reprint requests:** Azizah Ahmad Fauzi. Department of Clinical Oral Biology, Faculty of Dentistry, Universiti Kebangsaan Malaysia, Jalan Raja Muda Abdul Aziz, 50300 Kuala Lumpur, Malaysia. Tel: +603-92897888 Fax: +603-26982944 E-mail: azizah\_fauzi@ukm.edu.my

The use of external marker as a beam aiming device in bisecting-angle-technique is potentially effective to reduce the number of errors occurring during periapical radiography. In this study, 240 periapical radiographs were taken by undergraduate dental students. Periapical radiographs were taken using traditional method of bisecting-angle-technique (BAT), bisecting-angle-technique with the use of external marker (BAT-M) and the standard method in periapical radiography; paralleling technique (PT). All radiographic images were evaluated and errors were classified and tabled according to the type and number of errors. Chi-square test was used to compare the total number of radiographic errors made using these three techniques. One of the most common errors with BAT was cone cut error (13.8%). This error had been markedly reduced to 1.3% and 2.5% by implementation of BAT-M and PT, respectively. The total number of errors was also found to be significantly lesser for BAT-M compared to BAT,  $p < 0.05$ .

Keywords: errors, dental, radiography

---

## INTRODUCTION

In dentistry, periapical radiograph is commonly used for the assessment of tooth and its surrounding structures. There are two techniques which can be used for the taking of periapical radiograph. These techniques are paralleling technique and bisecting-angle-technique.

An ideal periapical radiograph is likely to be achieved when applying paralleling technique in comparison to bisecting-angle-technique (Mourshed & McKinney 1972; Gupta et al. 2014). Nevertheless, bisecting-angle-technique remains as an alternative modality to take periapical radiograph in cases that the image receptor cannot be placed parallel to the tooth such as in the presence of obstruction by tori, shallow palate, and shallow floor of mouth. This technique can be performed without the use of film holder and comfortable for the patient.

Vertical angulations guide as described by Gupta et al. (2014) has been recommended in order to reduce the chances of vertical error in bisecting-angle-technique. This angulations guide is used to assist in vertical alignment of the X-ray tube cone when performing periapical radiography with bisecting-angle-technique.

It is also important to identify external guide which can be used for proper horizontal alignment of the X-ray tube cone to the tooth of interest and image receptor in bisecting-angle-technique. Cone cutting and horizontal overlapping which are common errors with this technique (Rushton & Horner 1994), could be related to absence of external marker to align primary beam in horizontal manner particularly in less experienced operator. Thus, this study aimed to investigate the outcome of using external marker in bisecting-angle-technique in reducing periapical radiograph's errors by undergraduate

dental students.

In this study, a marked sticker on a phantom head was used as external marker to guide horizontal angulation of the X-ray tube when performing bisecting-angle-technique. The type and frequency of radiographic errors presented in periapical radiographs which were taken using bisecting-angle-technique with the use of external marker (BAT-M) were compared with the errors presented in the periapical radiographs which were performed by paralleling technique (PT) as well as traditional method of bisecting-angle-technique (BAT).

## MATERIALS AND METHODS

### SAMPLE COLLECTION

This study involved four final year undergraduate dental students each of whom performed 20 periapical radiographs (a full mouth periapical survey) using PT, BAT and BAT-M. The acquisition of 20 periapical projections within each technique by a student contributed to the total sample size of 240 periapical radiographs in this study.

### PREPARATION OF A WORKING MODEL

Each full mouth periapical survey performed by a dental student who participated in this study was carried out using a complete set of permanent dentition model mounted onto a simulation phantom head. This served as a working model (Figure 1) that

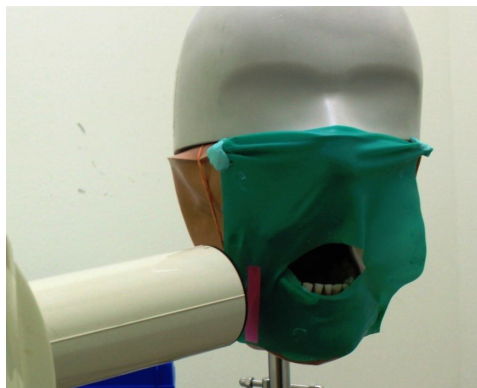

Figure 1: A working model used by students in this study. Noted here as well, a red rectangular sticker which was used as external marker in BAT-M.

simulated the human head to allow the students to perform multiple periapical exposures using three different techniques on a standardize subject. The preparation of this working model was summarized in Figure 2.

### RADIOGRAPHIC PROCEDURES

All students already underwent theoretical and practical session of the taking of periapical radiograph using the principle of PT and BAT. These techniques were taught to the students as part of their dental degree programme. In this study, the students were introduced to BAT-M for the first time. In BAT-M, all steps in BAT were followed. Additional procedure was performed by placing a rectangular shaped sticker (external marker) on the identified surface landmark. A demonstration session was conducted by a radiologist to demonstrate the placement of external marker on the selected region of the patient face, once the surface landmark of the tooth of interest was specifically identified

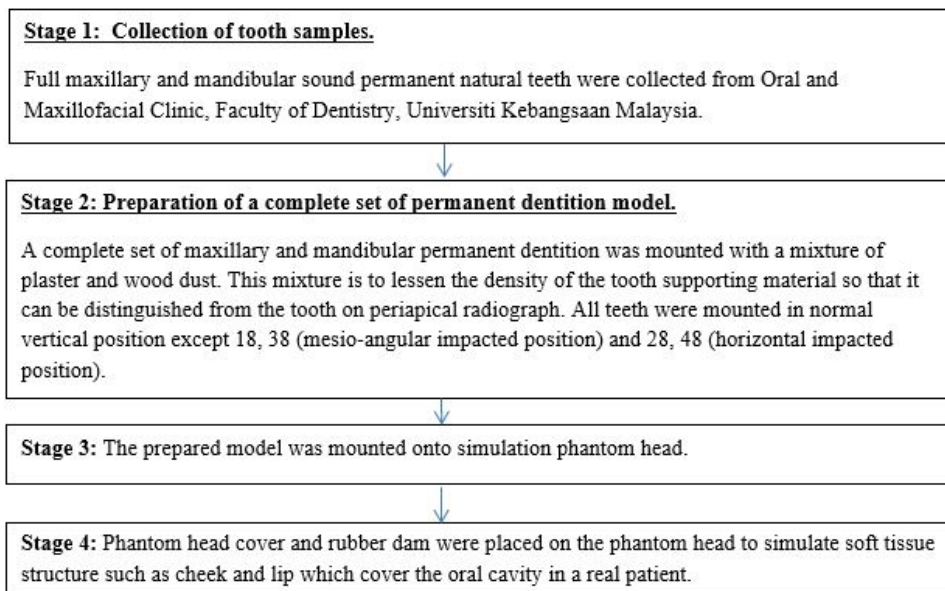


Figure 2: A flow-chart of a working model preparation.

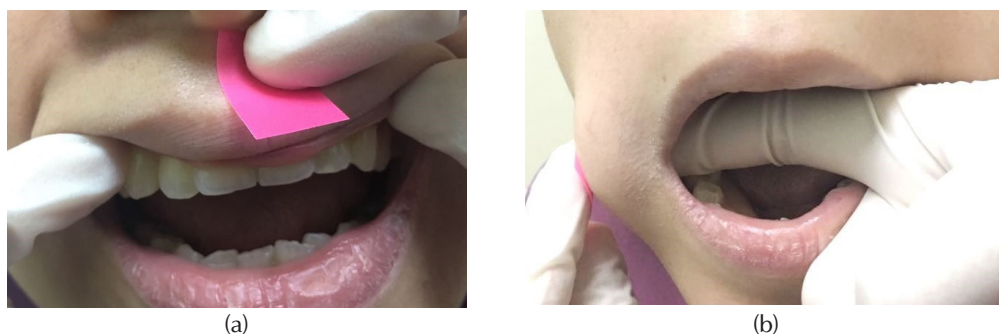

Figure 3: a) Identification of surface landmark of an anterior tooth by direct visualization of the tooth; b) For posterior teeth, an index finger is placed on the tooth of interest. At this level, the index finger is projected toward cheek until a soft tissue prominence can be seen to outline the specific region for the placement of the external marker.

(Figure 3a – 3b).

Next, a full mouth periapical survey was performed on the complete set of permanent dentition model which had been mounted onto the simulation phantom head. Periapical radiograph was acquired with intraoral X-ray machine (Sirona Heliodont Vario, operates at 70kVp) and digital film sensor (2.5cm x 1.5cm in size). A pre-radiographic full mouth periapical

examination was done by a trained radiographer to determine the site of teeth which can be adequately covered by the sensor (image receptor). All dental students were briefed to take full mouth periapical radiographs according to the 20 standardize region of tooth / teeth (11-12, 13, 14-15, 16-17, 18, 21-22, 23, 24-25, 26-27, 28, 31-32, 33, 34-35, 36-37, 38, 41-42, 43, 44-45, 46, 47-48).

Table 1: Type of errors presented in paralleling (PT), bisecting-angle-technique without marker (BAT) and bisecting-angle-technique with marker (BAT-M)

Type of Error	Number of Errors, x	Techniques		
		PT	BAT	BAT-M
Crown cut	x (%)	16(20.0%)	11(13.8%)	8(10.0%)
Apical cut		5(6.3%)	10(12.5%)	12(15.0%)
Cone cut		2(2.5%)	11(13.8%)	1(1.3%)
Horizontally misplaced sensor		13(16.3%)	9(11.3%)	7(8.8%)
Foreshortening image		-	-	-
Elongation image		-	3(3.8%)	2(2.5%)
Overlapping image		-	1(1.3%)	1(1.3%)
Sensor wire inclusion into image		1(1.3%)	-	-
Total errors		37(46.4%)	45(57.5%)	31(38.9%)

### REPRODUCIBILITY OF DIAGNOSTIC EVALUATION

All periapical radiographs were evaluated by a maxillofacial radiologist. Random samples of 22 radiographs were selected for evaluation by a maxillofacial radiologist with 4 wks interval between the first and second image assessment. Kappa statistic was carried out to analyse intra-observer agreement in deciding acceptability of the radiographs and the type of radiographic error which was significant in the radiographic images. The periapical radiograph must depict completely the crown and root of the tooth of interest in order to be diagnostically acceptable. In the diagnostically unacceptable radiograph, the most significant type of error was determined. The radiographic error which mainly contributed to the incomplete appearance of the tooth of interest was considered as the significant error in the periapical radiograph.

In this study, the radiographic errors were classified into eight types

(Table 1). Elongation was recorded when the image of the tooth of interest appeared lengthen and the root apex was obscured as a result of vertical misangulation of X-ray cone beam. Whereas, apical cut error was distinguished from elongation error when the image of the tooth of interest showed absence of root apex without the sign of tooth lengthening. On the other hand, periapical radiograph which showed loss of crown structure of the tooth of interest was recorded as crown cut. Horizontal misplacement of the sensor was recorded in the loss of mesial/distal part of the tooth of interest on the radiograph. Overlapping was recorded when 50% or more of the proximal surfaces of the tooth/teeth of interest were superimposed with the adjacent tooth/teeth. This type of error was due to horizontal misangulation of X-ray cone beam. In periapical radiograph with cone cutting error, the part of the tooth of interest was obscured as a result of incomplete coverage of X-ray cone to the sensor (without any misplacement of the sensor). Any radiographic errors which

Table 2: Chi-square test results comparing significant difference of error between techniques

Techniques Compared	Total number of errors	<i>p</i> -value	Significant difference
PT and BAT	PT: 37, BAT : 45	0.206	Not significant
PT and BAT-M	PT: 37, BAT-M: 31	0.337	Not significant
BAT and BAT-M	BAT: 45, BAT-M: 31	0.027	Significant

occur as a result of insufficient or over exposure time were excluded in this study.

## DATA COLLECTION AND ANALYSIS

Presence or absence of radiographic error in each periapical projection from each technique was recorded. In the presence of error, the type of error was determined. All data collected were entered into SPSS version 20 and the frequencies of errors in each technique were analysed. Chi-square test was used to compare total number of errors for these three techniques.

## RESULTS

In PT, the most common error recorded in this study was crown cut (20.0%) followed by horizontally misplaced sensor (16.3%), apical cut (6.3%) and cone cut (2.5%). BAT showed similar percentage in the frequency of both cone cut and crown cut errors (13.8%), while, BAT-M recorded cone cut and crown cut, 1.3% and 10%, respectively. By comparing the percentage of errors between these three techniques, the percentage of cone cutting error was highly reduced when PT and BAT-M was performed. Table 1 summarized the number and percentage of errors presented in all of the techniques.

Comparison between BAT and PT showed higher total number of errors in BAT. When external marker was applied in BAT, the total number of errors had been found lesser with this technique in comparison to PT. However, chi-square test (Table 2) showed no significant association between PT and BAT ( $p=0.206$ ), as well as, PT and BAT-M ( $p=0.337$ ). On the other hand, comparison between BAT and BAT-M (Table 2) showed significantly lesser total number of errors in BAT-M,  $p<0.05$ .

In this study, the level of intra-observer agreement for determination of periapical radiograph diagnostic acceptability and type of periapical radiographic error was excellent, kappa ( $\kappa$ ) value: 0.92.

## DISCUSSION

The most common radiographic error produced in all techniques performed in this study was resulted from misplacement of sensor either in horizontal or vertical direction. Misplacement of sensor in vertical direction can lead to crown cut or apical cut of the periapical images. This finding is contradictory with previous study by Haghnegahdar et al. (2013) who described cone cutting as the most common error in periapical radiograph. In this study, we used only

one type of sensor for the taking of both anterior and posterior periapical radiographs. Thus, the limitation of the sensor size requires the operator to accurately place the sensor at the selected region of interest which can be difficult for a less experienced operator to comply. Hence, increase in the frequency of sensor misplacement errors in this study.

In BAT, cone cutting (13.8%) has been found as the next common error following the error in vertical misplacement of the sensor. This error is due to misalignment of X-ray cone which does not completely cover the tooth of interest and the image receptor. Applying external marker in BAT appears to be an effective way to overcome the common problem with this technique. As demonstrated in this study, the application of BAT-M has markedly reduced the frequency of cone cutting error towards 1.3%. This percentage is comparable to the frequency of cone-cutting error with the standard technique, PT.

Few elongation and overlapping errors were recorded in both BAT and BAT-M in this study. These type of errors were absent in PT. As described by Kazzi and colleagues (Kazzi et al. 2007), this study also supports the use of PT in reducing overlapping error and misangulation error of X-ray cone beam in vertical manner. In PT, the image receptor holder device equips with external rod and external collimator ring. In this study, the absence of elongation and overlapping errors with PT suggested that external rod had been useful to eliminate the problem with misangulation of X-ray

cone beam in vertical direction, while, external collimator ring had been useful to assist the operator in aligning X-ray cone beam parallel to the buccal surface the tooth of interest. Hence, the collimator ring eliminates the overlapping error on the radiographic image.

By comparing BAT-M and PT, less total number of errors was found in BAT-M. However, it was statistically not significant. In clinical situation, the accuracy of image has to be taken into account when selecting periapical radiographic techniques. Several studies (Rushton & Horner 1994; Coelho et al. 2007; Takeshita et al. 2014) have shown that radiographic images acquired using PT were generally more accurate than images acquired with bisecting-angle-technique. Thus, PT is still recommended as first line approach in periapical radiography since no significant association in the total number of errors was found between PT and BAT-M.

However, when bisecting-angle-technique is indicated such as in shallow palate, it is recommended to use X-ray beam aiming device such as external marker as described in this study to guide the actual position of tooth of interest as well as the image receptor prior to periapical radiographic exposure. This in turns, reduce the chances of radiographic error particularly the cone cutting error.

The limitation of this study was the difficulty to achieve adequate bite support between maxillary and mandibular teeth which were mounted on simulation phantom head

when performing PT. This limitation could also contribute to the vertical miss-placement of the sensor which appear as apical cut or crown cut on radiographic image. In human subject, the presence of surrounding muscles to support the occlusion between maxillary and mandibular teeth may overcome the limitation of this study. Thus, further study is required to compare these techniques in clinical trials.

### CONCLUSION

BAT-M provides significant reduction in radiographic errors made by undergraduate dental students. In cases where bisecting-angle-technique is indicated, the use of external marker is recommended to reduce the chances of radiographic errors and repeated X-ray exposure.

### ACKNOWLEDGEMENT

The authors would like to thank all dental radiology staff especially Ms. Siti Sarah and Mr. Mohd Amir Sufian for assisting in the preparation of radiographic equipment. The authors also acknowledge Mr. Muhd Fazly Nizam Rashdi for his assistance in the statistical analysis, as well as Noor Hanani Ahmad Damanhuri and Izzat

Zainal who had participated in the taking of radiographic projections for this study. This study was supported by Universiti Kebangsaan Malaysia research grant, GGPM-2014-049.

### REFERENCES

- Coelho, R.M., Sumas, K.S., Oliveira-Junior, I.S., Manzi, F.R. 2017. Comparison of radiographic film holders considering periodontal aspects. *Periodontia* 17(3): 80-8.
- Gupta, A., Devi, P., Srivastava, R., Jyoti, B. 2014. Intra oral periapical radiography - basics yet intrigue: A review. *Bangladesh Journal of Dental Research & Education* 4(2): 83-7.
- Haghnegahdar, A., Bronoosh, P., Taheri, M.M., Farjood, A. 2013. Common intra oral radiographic errors made by dental students. *Galen Medical Journal* 2(2): 44-8.
- Kazzi, D., Horner, K., Qualtrough, A.C., Martinez-Beneyto, Y., Rushton, V.E. 2007. A comparative study of three periapical radiographic techniques for endodontic working length estimation. *Int Endod J* 40(7): 526-31.
- Mourshed, F., McKinney, A.L. 1972. A comparison of paralleling and bisecting radiographic techniques as experienced by dental students. *Oral Surg Oral Med Oral Pathol* 33(2): 284-96.
- Rushton, V.E., Horner, K. 1994. comparative study of radiographic quality with five periapical techniques in general dental practice. *Dentomaxillofac Radiol* 23(1): 37-45.
- Takeshita, W.M., Vessoni Iwaki, L.C., Da Silva, M.C., Tonin, R.H. 2014. Evaluation of diagnostic accuracy of conventional and digital periapical radiography, panoramic radiography, and cone-beam computed tomography in the assessment of alveolar bone loss. *Contemp Clin Dent* 5(3): 318-23.

Received: 28 April 2017

Accepted: 23 October 2017