

## CASE REPORT

## When Dermatomyositis Patient Has Blurring of Vision – What Goes Wrong?

CHRISTINA NG WK<sup>1,2</sup>, HANIZASURANA H<sup>1</sup>, NOR AZITA AT<sup>3</sup>,  
NOR FARIZA N<sup>4</sup>, ZABRI K<sup>1</sup>

<sup>1</sup>Department of Ophthalmology, Hospital Selayang, Lebuhraya Selayang-Kepong, 68100 Batu Caves, Selangor, Malaysia.

<sup>2</sup>Department of Ophthalmology, Faculty of Medicine, Universiti Kebangsaan Malaysia Medical Centre, Jalan Yaacob Latif, Bandar Tun Razak, 56000 Cheras, Kuala Lumpur, Malaysia.

<sup>3</sup>Department of Ophthalmology, Hospital Kuala Lumpur, Jalan Pahang, 50586 Kuala Lumpur, Malaysia.

<sup>4</sup>Department of Ophthalmology, Hospital Shah Alam, Persiaran Kayangan, Seksyen 7, 40000 Shah Alam, Selangor, Malaysia.

### ABSTRAK

*Cytomegalovirus (CMV) retinitis merupakan penyakit yang berlaku pada pesakit yang menghadapi Human Immunodeficiency Virus (HIV) terutamanya. Ia juga dilaporkan pada pesakit tanpa HIV, contohnya pesakit yang menghadapi gangguan autoimun yang memerlukan immunosuppresif, pesakit menjalani pemindahan organ atau sumsum tulang, pesakit kanser darah atau payudara yang menerima kemoterapi, penyakit mata berikutan suntikan kortikosteroid intraokular atau periokular, kencing manis dan Good sindrom. Walau bagaimanapun, kes CMV retinitis dalam pesakit yang menghadapi dermatomyositis dan kanser pada masa yang sama tidak pernah dilaporkan sebelum ini. Ia juga tidak dilaporkan dalam kanser selain kanser darah atau payudara, atau pesakit kanser sebelum menerima rawatan kemoterapi. Kami melaporkan kes CMV retinitis dalam seorang wanita tanpa HIV berusia 40 tahun yang menghadapi dermatomyositis dan kanser paru-paru, di mana CMV retinitisnya kembali apabila immunosuppresif dimula semula. Kedua-dua episod CMV retinitis telah berjaya dirawat selepas mengambil kira keadaan keimunannya.*

*Kata kunci:* cytomegalovirus retinitis, dermatomyositis, kanser paru-paru

### ABSTRACT

Cytomegalovirus (CMV) retinitis occurs predominantly in Human Immunodeficiency Virus (HIV) -infected patients. It was also reported in HIV-seronegative patients with systemic autoimmune disorder requiring systemic immunosuppression, organ

**Address for correspondence and reprint requests:** Christina Ng Wei Khee. Department of Ophthalmology, Hospital Selayang, Lebuhraya Selayang-Kepong, 68100 Batu Caves, Selangor, Malaysia/ Department of Ophthalmology, Universiti Kebangsaan Malaysia Medical Centre, Jalan Yaacob Latif, Bandar Tun Razak, 56000 Cheras, Kuala Lumpur, Malaysia. Tel: +603-61263333 Fax: +603-61371652 E-mail: christinangwk@gmail.com

or bone marrow transplantation, haematological or breast malignancy receiving chemotherapy, ocular diseases following intraocular or periocular corticosteroid injection, diabetes mellitus and Good syndrome. However, CMV retinitis in patients with concurrent dermatomyositis and malignancy has not been previously reported. It has not been reported in cancer other than haematological or breast malignancy, or in cancer patient prior to chemotherapy. We report a case of 40-year-old HIV-seronegative woman with underlying dermatomyositis and lung malignancy who developed right CMV retinitis which relapsed after recommencement of immunosuppressant. Both episodes of CMV retinitis were successfully treated after taken her immunocompromised state into consideration.

Key-words: cytomegalovirus retinitis, dermatomyositis, lung neoplasms

---

## INTRODUCTION

Cytomegalovirus (CMV) retinitis is an opportunistic eye infection characterized by dense, white confluent opacification of the retina along the vessels with retinal haemorrhage and vascular sheathing. It predominantly occurs in patients with acquired immunodeficiency syndrome (AIDS) with CD4 cell counts less than 50 cells/mm<sup>3</sup>. It has also been reported in Human Immunodeficiency Virus (HIV)-seronegative patients with systemic autoimmune disorder requiring systemic immunosuppression, organ or bone marrow transplantation; haematological or breast malignancy receiving chemotherapy; ocular diseases following intraocular or periocular corticosteroid injection; diabetes mellitus and Good syndrome (Kim et al. 2007; Han et al. 2015; Downes et al. 2016).

Dermatomyositis is an idiopathic inflammatory myopathy with characteristic skin manifestations. It has a strong association with

malignancy including ovarian, lung, breast, pancreatic, stomach, colorectal, nasopharyngeal cancers, and non-Hodgkin lymphoma (Olazagasti et al. 2015). The reported incidence of cancer associated with dermatomyositis varies from less than 7% to over 30% (Di Rollo et al. 2014).

CMV retinitis in patients with i) concurrent dermatomyositis and malignancy, ii) cancer other than haematological or breast malignancy, or iii) cancer prior to chemotherapy has not been previously reported. We describe a case of CMV retinitis in a HIV-seronegative patient diagnosed with dermatomyositis and lung malignancy.

## CASE REPORT

A 40-year-old woman with dermatomyositis complained of right eye blurred vision and floaters for three weeks. She was on oral Azathioprine 100mg OD, oral prednisolone 15mg OD and hydroxychloroquine 300mg OD for 13 months. Examination revealed right vision of 6/18 with no relative afferent

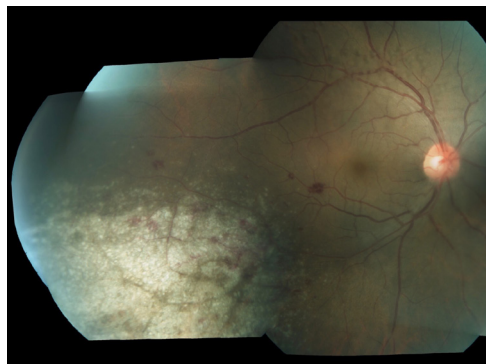


Figure 1: Right fundus examination revealed hemorrhagic retinitis along the inferotemporal vessel and vitreous condensation along superotemporal vessel

pupillary defect. Anterior segment examination was unremarkable. Right fundus showed haemorrhagic retinitis along inferotemporal vessel with presence of vitreous condensation (Figure 1). CMV retinitis was confirmed by positive polymerase chain reaction (PCR) from vitreous fluid. Vitreous PCR for Herpes simplex 1 & 2 and Varicella zoster were not detected. HIV serology was negative and she was not diabetic. Her absolute lymphocyte count was  $0.67 \times 10^9/L$ . The patient was started on daily intravenous Ganciclovir 5mg/kg BD for two weeks and biweekly intravitreal Ganciclovir 2mg/0.1 ml. Azathioprine was withheld in view that the retinitis was most probably due to immunosuppressive state. Oral prednisolone was reduced to 10mg OD. Her vision improved to 6/9 and lesions resolved (Figure 2). Absolute neutrophil count at the end of antiviral therapy was  $2.60 \times 10^9/L$  while absolute lymphocyte count increased to  $1.10 \times 10^9/L$ . Due to financial reasons and non-availability of oral valganciclovir in our hospital, patient was not able to be

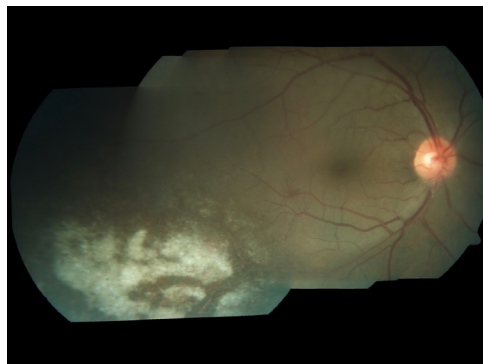


Figure 2: Resolving retinal lesion at one month following treatment

started on the maintenance Ganciclovir, nevertheless intravitreal Ganciclovir was continuously given as biweekly till the lesion become scarred. At week 3 when the retinitis became inactive, the intravitreal Ganciclovir was stopped.

After a month without Azathioprine, her systemic disease flared up. She had severe generalized skin itchiness and redness, Heliotrope rash, Gottron papules and proximal myopathy. Oral Azathioprine 50mg OD was recommenced and skin condition was controlled.

A month later, right eye CMV retinitis was reactivated with the lesion approaching the macula (Figure 3). Azathioprine was withheld again. She was treated with biweekly intravitreal Ganciclovir for four weeks. The retinitis subsequently resolved with 6/9 vision (Figure 4). Skin condition was otherwise status quo. The patient opted to discontinue azathioprine in fear that the retinitis would recur. Contralateral eye was not involved throughout the follow-up.

Three months later, the patient developed pathological lumbar fracture. A magnetic resonance imaging of spine

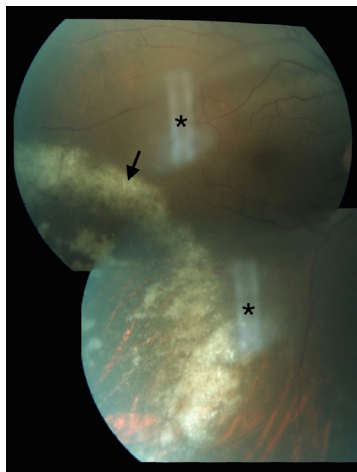

Figure 3: Reactivation of right eye CMV retinitis (arrow) that was approaching the macula. Artifacts were marked with asterisk (\*)

incidentally revealed a lung mass. The patient refused for lung biopsy and was diagnosed with presumed stage IV lung malignancy with bone metastasis. She declined chemotherapy and immunosuppressant; and defaulted all follow up. According to the phone interview, her ocular symptoms did not recur. She passed away ten months after the diagnosis of lung malignancy.

## DISCUSSION

CMV retinitis was well recognized in patients receiving immunosuppressant. This is evidenced in a study, where CMV antigenemia was detected in 60% of patients taking prednisolone of more than 30 mg/day, suggesting that CMV infection occurs with high frequency during immunosuppressive therapy (Yoshihara et al. 1999). In patients with inflammatory connective tissue disease, CMV DNA which was previously not present prior to immunosuppressive therapy, was detected in peripheral

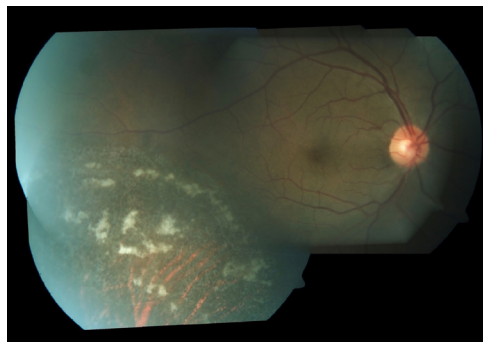


Figure 4: Resolution of recurrent retinitis following four weeks of intravitreal Ganciclovir

blood leukocytes in 70% of patients after receiving immunosuppressant. This signifies a high risk of CMV reactivation in patients requiring immunosuppression (Mori et al. 2004). In this case, we believed that recommencement of Azathioprine after the first course of systemic Ganciclovir promoted the reactivation of CMV infection.

Another reason contributing the recurrence was the patient might already have lung malignancy during the event of CMV retinitis. The chronicity of the advance malignancy as evident by bone metastasis could further suppress the patient's immune state. To date, CMV retinitis was reported in patients with leukemia, lymphoma, and multiple myeloma during or after receiving maintenance therapy (Han et al. 2015; Downes et al. 2016). Only one case was reported in breast malignancy (Downes et al. 2016). However, incidence of CMV retinitis in lung malignancy, or in malignancy prior to chemotherapy has not been previously reported.

Although dermatomyositis itself can compromise host immunity, it is less likely in this case because the disease

activity of dermatomyositis was not significant at the time of diagnosis of both CMV retinitis and its reactivation (Ku et al. 1999). CMV retinitis did not recur despite the patient was no longer on immunosuppressant thereafter.

This patient was given an initial 'induction' course of systemic Ganciclovir for 14 days to inactivate CMV while preventing systemic spread and further enlargement of retinal lesions. Ideally, maintenance treatment with oral Valganciclovir is the best option following induction course. Moreover it would be expected for the patient to develop recurrent CMV retinitis when azathioprine was reinstated. However, oral Valganciclovir is too costly, therefore she chose to have intravitreal Ganciclovir whenever disease gets reactivated. Another reason intravitreal Ganciclovir chosen as alternate treatment modality for reactivation was to avoid any possible systemic effect it may have on the bone marrow. This is because systemic Ganciclovir therapy can cause myelosuppression, hence an already compromised immune system may be further suppressed (Langner-Wegscheider et al. 2010). Fortunately, our patient showed a quick response to Ganciclovir in both events. In cases of resistance, other choices of treatment include Foscarnet and Cidofovir, however all of which are virustatic (Au Eong et al. 1999).

Visual outcome in this patient was promising as the CMV retinitis was detected early. Although maintenance treatment could not be given, close monitoring and intensive intravitreal injection were able to secure her vision. At times, vision remains the

main concern of the patient, as the patient was willing to discontinue Azathioprine for the fear of recurrence of CMV retinitis.

## CONCLUSION

It is a great challenge for both ophthalmologists and rheumatologists to treat concurrent CMV retinitis and dermatomyositis. As the damage to the retina caused by CMV retinitis is permanent, early detection of the disease remains critical in preserving the vision. Patients on immunosuppressant have to be warned of risk of CMV retinitis and should be educated about reporting visual disturbances (floaters, blurred vision, or scotoma). Close follow-up by ophthalmologists is at utmost importance because CMV retinitis usually occurs in periphery retina and patients might remain asymptomatic. Co-management with rheumatologists is essential for monitoring of the systemic disease, adjustment of immunosuppressant and malignancy screening in dermatomyositis.

## REFERENCES

- Au Eong, K.G., Beatty, S., Charles, S.J. 1999. Cytomegalovirus retinitis in patients with acquired immune deficiency syndrome. *Postgrad Med J* 75(888): 585-90.
- Di Rollo, D., Abeni, D., Tracanna, M., Capo, A., Amerio, P. 2014. Cancer risk in dermatomyositis: a systematic review of the literature. *G Ital Dermatol Venereol* 149(5): 525-37.
- Downes, K.M., Tarasewicz, D., Weisberg, L.J., Cunningham, E.T. 2016. Good syndrome and other causes of cytomegalovirus retinitis in HIV-negative patients-case report and comprehensive review of the literature. *J Ophthalmic Inflamm Infect* 6(1): 3.
- Han, S.B., Lee, J.H., Lee, J.W., Chung, N.G., Cho, B., Kang, J.H., Kim, H.K., Lee, J.H., Lee, W.K. 2015. Cytomegalovirus retinitis diagnosed

- after completion of chemotherapy for acute lymphoblastic leukemia in an adolescent. *J Pediatr Hematol Oncol* 37(2): e128-e130.
- Kim, H.R., Kim, S.D., Kim, S.H., Yoon, C.H., Lee, S.H., Park, S.H., Kim, H.Y. 2007. Cytomegalovirus retinitis in a patient with dermatomyositis. *Clin Rheumatol* 26(5): 801-3.
- Ku, S.C., Yu, C.J., Chang, Y.L., Yang, P.C. 1999. Disseminated cytomegalovirus disease in a patient with systemic lupus erythematosus not undergoing immunosuppressive therapy. *J Formos Med Assoc* 98(12): 855-8.
- Langner-Wegscheider, B.J., ten Dam-van Loon, N., Mura, M., Faridpooya, K., de Smet, M.D. 2010. Intravitreal ganciclovir in the management of non-AIDS-related human cytomegalovirus retinitis. *Can J Ophthalmol* 45(2): 157-60.
- Mori, T., Kameda, H., Ogawa, H., Iizuka, A., Sekiguchi, N., Takei, H., Nagasawa, H., Tokuhira, M., Tanaka, T., Saito, Y., Amano, K., Abe, T., Takeuchi, T. 2004. Incidence of cytomegalovirus reactivation in patients with inflammatory connective tissue diseases who are under immunosuppressive therapy. *J Rheumatol* 31(7): 1349-51.
- Olazagasti, J.M., Baez, P.J., Wetter, D.A., Ernste, F.C. 2015. Cancer risk in dermatomyositis: a meta-analysis of cohort studies. *Am J Clin Dermatol* 16(2): 89-98.
- Yoshihara, S., Fukuma, N., Masago, R. 1999. Cytomegalovirus infection associated with immunosuppressive therapy in collagen vascular diseases. *Ryumachi* 39(5): 740-8.