

## CASE REPORT

# Thymoma: A Case Report and Review of the Literature

Hamidah A<sup>1</sup>, Poulsaeman V<sup>1</sup>, Suria AA<sup>2</sup>, Zarina AL<sup>1</sup>, Zulfiqar MA<sup>3</sup>, Jamal R<sup>1</sup>

*Department of <sup>1</sup>Paediatrics, <sup>2</sup>Pathology and <sup>3</sup>Radiology, Faculty of Medicine, Universiti Kebangsaan Malaysia, Kuala Lumpur*

## ABSTRAK

Timoma merangkumi 1% dari keseluruhan kanser mediastinum dan jarang berlaku pada kanak-kanak. Secara tipikal, kanser ini adalah agresif dan kadar sembuh adalah rendah. Rawatan semasa untuk timoma invasif meliputi pelbagai disiplin. Seorang pesakit berumur 16 tahun telah di diagnosis dengan kanser timoma invasif. Pesakit ini telah berjaya dirawat dengan kimoterapi di ikuti dengan pembedahan dan radioterapi. Setakat ini, pesakit berada dalam keadaan 'remission' yang berterusan selama 6 tahun selepas tamat rawatan.

*Kata kunci:* timoma, kimoterapi, pembedahan, iradiasi

## ABSTRACT

Thymomas comprise about 1% of all mediastinal tumours and are rare in children. Typically, these tumours are aggressive, with a poor outcome. The current treatment of invasive thymoma is often multidisciplinary. We report a 16-year-old boy with invasive thymoma who was successfully treated with systemic chemotherapy, surgical resection and irradiation. The patient has been in continuous remission for 6 years without radiographic evidence of tumour recurrence.

*Key words:* thymoma, chemotherapy, surgical resection, irradiation

## INTRODUCTION

Primary thymic lesions such as thymic cysts, hyperplasia, carcinoma, and thymomas comprise approximately 2-3% of all pediatric mediastinal tumours (Grosfeld 1994). Thymoma is a tumour originating within the epithelial cells of the thymus. Patients can present with chest pain, cough, dyspnoea, dysphagia,

hoarseness, superior vena cava syndrome or paraneoplastic syndrome including myasthenia gravis, pure red cell aplasia, or acquired hypogammaglobulinaemia, and connective tissue disease disorders. Most patients are asymptomatic. Thymoma can generally be categorised as non-invasive (Stage I) and invasive (Stage II-IV) (Masaoka et al. 1981). Treatment of thymoma includes

**Address for correspondence and reprint requests:** Assoc. Prof. Dr. A. Hamidah, Department of Paediatrics, Faculty of Medicine, Universiti Kebangsaan Malaysia, Jalan Yaacob Latif, Bandar Tun Razak, 56000 Cheras, Kuala Lumpur. Tel: 603-91456637. Fax: 603-91737827. Email: midalias@ppukm.ukm.my

surgery, chemotherapy, and irradiation. Surgical resection is the treatment of choice for stage I and stage II tumours. In more advanced diseases, systemic therapy has shown to give a response rate of 50% to 80% (Thomas et al. 1999). Therefore, a multimodal therapy is often used for the treatment of patients with advanced thymoma. Stage of the tumour is an independent prognostic factor for survival.

## CASE REPORT

A 16-year-old boy was evaluated for cough and chest pain. His past medical history was unremarkable. On physical examination, the patient showed signs of mild superior vena cava (SVC) obstruction, with decreased right chest breath sounds. Other physical examination findings were normal. An initial chest X-ray showed a huge mass in the anterior mediastinum. Computerized tomography (CT) of the thorax showed an anterior mediastinal mass with a diameter of 6x10x11cm that abutted the great vessels and had posteriorly displaced and compressed the SVC (Figure 1). The patient underwent a CT-guided percutaneous biopsy of the mediastinum mass as it was considered inoperable. Histopathological examination revealed a neoplasm composed of epithelial cells with surrounding lymphoplasmacytic infiltration (Figure 2). The neoplastic epithelial cells display round to oval vesicular nuclei. Immunohistochemically, the neoplastic cells were positive for cytokeratin and negative for LCA, vimentin, and S-100, confirming the diagnosis of thymoma.

Neoadjuvant chemotherapy was started to improve resectability of the tumour mass. A chemotherapy protocol containing cisplatin (50mg/m<sup>2</sup>/day, for 1 day), cyclophosphamide (500mg/m<sup>2</sup>/day, for 1 day), and doxorubicin (50mg/m<sup>2</sup>/day, for 2 days) was given and repeated every 21 days. After 3 cycles of chemotherapy,

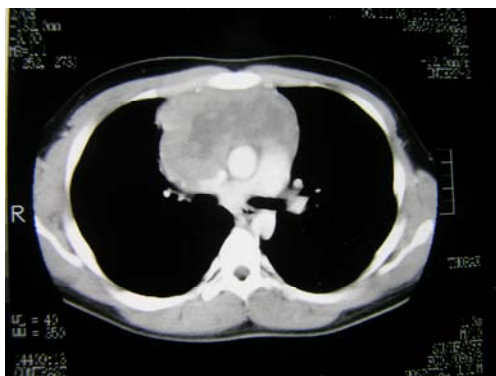

Figure 1: CT of thorax showed an anterior mediastinum mass with a diameter of 6x10x11cm that abutted the great vessels and posteriorly displaced and compressed the SVC.

about 50% reduction in tumour size was observed on a repeat CT scan of the thorax (mass size: 5.4x4.6x7.5cm). Subsequently, he was scheduled for a tumour excision, however, the surgery was performed after the 4th cycle of chemotherapy. At the time of median sternotomy, the mass was densely adhered to the underlying pericardium, brachio-cephalic vein, SVC, and right upper lobe of the lung. The tumour had completely encased the right phrenic nerve and had infiltrated the wall of the SVC anterolaterally and the wall of the brachio-cephalic vein anteriorly. Incomplete resection of the tumour was performed together with resection of the involved pericardium. A small rim of the tumour tissue that had infiltrated the SVC and the brachio-cephalic vein walls could not be excised. Final pathology showed thymoma with unclear margins, consistent with the World Health Organization (WHO) classification of thymoma type B2 and the Masaoka classification of stage III.

Post-operatively the patient received two cycles of chemotherapy; however, a residual tumour of 2.0x1.0x0.5cm was seen on a repeat CT scan of thorax. Subsequently, the patient was treated with 30Gy radiotherapy in 15 fractions at 2.0 Gy per fraction to the tumour area

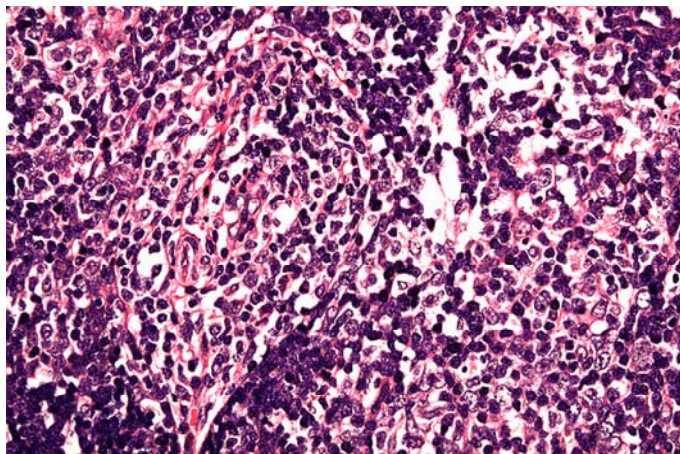


Figure 2: Section shows foci of neoplastic epithelial cells with surrounding lymphoplasmacytic cell infiltration. These neoplastic epithelial cells display round to oval vesicular nuclei and some with distinct nucleolus (Hematoxylin and eosin stain, x100).

followed by boosts of 16Gy in 8 fractions at 2.0 Gy per fraction over a period of 4 weeks. The tumour had cleared on repeat CT scan of thorax at the end of the treatment. The patient has been in remission for 6 years without radiographic evidence of tumour recurrence.

## DISCUSSION

Thymoma is uncommon in children. Therefore, it is important to recognise this tumour as distinct from others like mediastinal teratoma, lymphoma, malignant histiocytoma and Ewing sarcoma/primitive neuroectodermal tumour. Most thymomas are confined to the mediastinum at the time of diagnosis. Distant metastasis is rare.

The widely accepted staging system in use for thymoma is that proposed by Masaoka et al. (1981), based on a post-operative staging procedure, since capsular invasion, a key component of this staging system, is best evaluated by pathologic examination. Recently, the WHO classification of thymic tumours (Rosai & Sobin 1999) based on the histological assessment of the morphology of the neoplastic epithelial cells has received increasing acceptance, and it has been

shown to be of prognostic significance (Chen et al. 2002; Kondo et al. 2004). Thymomas are classified as type A, AB, and B in the WHO classification, and exhibit organotypic (thymus-like) architectural features. Nevertheless, Kim et al. (2010) reported that the prognostic relevance among type B thymoma subtypes is still controversial. They did not find any significant differences in the incidence of recurrence and survival among the three subtypes of type B thymomas. Tumour recurrence was significantly associated with advanced Masaoka stages. Some have shown that patients with type B3 thymomas have worse prognoses than those with type B2 thymomas (Okumura et al. 2002; Nakagawa et al. 2003), whereas others have reported a similar survival rate between these two groups (Chen et al. 2002; Ströbel et al. 2004). Therefore, Masaoka stage should always be considered when predicting prognosis and planning treatment, including adjuvant treatment for patients with type B thymomas.

Surgical resection is the mainstay of treatment in patients with resectable disease (Yagi et al. 1996; Wang et al. 1992). The extent of surgical resection remains the most important prognostic

factor for predicting tumour relapse (Singhal et al. 2003). Dhall et al. (2004) reported two children with completely encapsulated thymoma who were successfully treated with surgery alone, and remain free of disease 3 years after surgery. However, multimodal therapy consisting of chemotherapy, radiotherapy, and/or surgery is recommended for any incompletely resected "high-risk" thymoma, locally advanced or metastatic thymoma (Chahinian et al. 1981; Ströbel et al. 2005). It has been shown that multimodal treatment of patients with neoadjuvant chemotherapy, and surgery, followed by additional adjuvant chemotherapy plus radiotherapy, may improve the survival of patients with locally advanced thymoma (Venuta et al. 1997; Hassan & Seoud 2009). In addition, induction chemotherapy may be effective in downstaging thymoma, allowing patients initially thought not to be surgical candidates to undergo resection.

Our patient had advanced tumour stage III Masaoka classification. The benefit of multimodal therapy was demonstrated in our patient as the patient showed a partial response to the induction chemotherapy improving the resectability of the mass during surgery. Although "debulking" or subtotal resection have been reported for invasive thymoma, most modern day series have demonstrated long term survival correlating best with complete surgical removal. Therefore, we believe most surgeons would likely perform en bloc great vein and phrenic nerve resection in this case. Removal of one brachiocephalic vein is usually well tolerated and there are a number of techniques to reconstruct the SVC. Diaphragmatic plication could also be performed to improve breathing mechanics after phrenic nerve removal, which may be dysfunctional from tumour involvement to begin with. Subsequently, the postoperative adjuvant chemotherapy

and radiotherapy further help to clear the tumour in this patient. Previously, Shin et al. (1998) reported that induction chemotherapy consisted of cyclophosphamide, doxorubicin, and cisplatin was given to patients with unresectable stage III and IV thymoma. Out of 11 patients initially thought to be unresectable, nine were able to undergo resection. All nine patients were given additional postoperative adjuvant chemotherapy and radiotherapy. Out of these patients, seven were disease-free at a median follow-up period of 43 months. Yokoi et al. (1992) reported a successful treatment with preoperative/postoperative cisplatin and doxorubicin, in addition to postoperative radiotherapy in a patient with a locally advanced thymoma invading the heart and great vessels. Macchiarini et al. (1991) reported that four patients with clinical stage III thymoma received three cycles of cisplatin, epirubicin, and etoposide before surgery, and later achieved a complete remission. Rea et al. (1993) reported that 16 patients with stage III and IVa disease were treated with a doxorubicin, cisplatin, vincristine, and cyclophosphamide regimen every three weeks for three to four cycles. After chemotherapy, surgery was performed, and if residual disease was present, postoperative radiation therapy was given. Patients with a complete remission received three additional cycles of chemotherapy. The authors demonstrated seven complete and five partial responses and a projected two-year survival rate of 80%. Loehrer et al. (1997) reported a response rate of around 70% in 23 patients with stage III thymoma who received chemoradiotherapy. The progression-free and overall survival rates at five years were 54% and 52% respectively.

As demonstrated in this patient, the use of multimodal therapy in locally advanced thymoma was effective, significantly decreasing the tumour size, thus improving

the patient's surgical outcome, and overall contributed to a good long-term outcome.

## REFERENCES

- Chahinian, A.P., Bhardwaj, S., Meyer, R.J., Jaffrey, I.S., Kirschner, P.A. & Holland, J.F. 1981. Treatment of invasive or metastatic thymoma: Report of eleven cases. *Cancer* **47**: 1752-1761.
- Chen, G., Marx, A., Wen-Hu, C., Yong, J., Puppe, B., Stroebel, P. & Mueller-Hermelink, H.K. 2002. New WHO histologic classification predicts prognosis of thymic epithelial tumors: A clinicopathologic study of 200 thymoma cases from China. *Cancer* **95**: 420-429.
- Dhall, G., Ginsburg, H.B., Bodenstein, L., Fefferman, N.R., Greco, M.A., Chang, M.W. & Gardner, S. 2004. Thymoma in children: Report of two cases and review of literature. *J Pediatr Hematol Oncol* **26**: 681-685.
- Grosfeld, J.L. 1994. Primary tumors of the chest wall and mediastinum in children. *Semin Thorac Cardiovasc Surg* **6**:235-239.
- Hassan, M. & Seoud, D.E. 2009. Multimodality treatments in locally advanced stage thymomas. *Hematol Oncol Stem Cell Ther* **2**: 340-344.
- Kim, H.K., Choi, Y.S., Kim, J., Shim, Y.M., Han, J. & Kim, K. 2010. Type B thymoma: Is prognosis predicted only by World Health Organization classification? *J Thorac Cardiovasc Surg* **139**: 1431-1435.e1.
- Kondo, K., Yoshizawa, K., Tsuyuguchi, M., Kimura, S., Sumitomo, M., Morita, J., Miyoshi, T., Sakiyama, S., Mukai, K. & Monden, Y. 2004. WHO histologic classification is a prognostic indicator in thymoma. *Ann Thorac Surg* **77**: 1183-1188.
- Loehrer, P.J., Chen, M., Kim, K.M., Aisner, S.C., Einhorn, L.H., Livingston, R. & Johnson, D. 1997. Cisplatin, doxorubicin and cyclophosphamide plus thoracic radiation therapy for limited stage, unresectable thymoma: An intergroup trial. *J Clin Oncol* **15**: 3093-3099.
- Macchiarini, P., Chella, A., Ducci, F., Rossi, B., Testi, C., Bevilacqua, G. & Angeletti, C.A. 1991. Neoadjuvant chemotherapy, surgery, and postoperative radiation therapy for invasive thymoma. *Cancer* **68**: 706-713.
- Masaoka, A., Monden, Y., Nakahara, K. & Tanioka, T. 1981. Follow-up study of thymoma with special reference to their clinical stages. *Cancer* **48**: 2485-2492.
- Nakagawa, K., Asamura, H., Matsuno, Y., Suzuki, K., Kondo, H., Maeshima, A., Miyaoka, E. & Tsuchiya R. 2003. Thymoma: A clinicopathologic study based on the new World Health Organization classification. *J Thorac Cardiovasc Surg* **126**: 1134-1140.
- Okumura, M., Ohta, M., Tateyama, H., Nakagawa, K., Matsumura, A., Maeda, H., Tada, H., Eimoto, T., Matsuda, H. & Masaoka, A. 2002. The World Health Organization histologic classification system reflects the oncologic behavior of thymoma: A clinical study of 273 patients. *Cancer* **94**: 624-632.
- Rea, F., Sartori, F., Loy, M., Calabrò, F., Fornasiero, A., Daniele, O. & Altavilla, G. 1993. Chemotherapy and operation for invasive thymoma. *J Thorac Cardiovasc Surg* **106**: 543-549.
- Rosai, J. & Sobin, L. 1999. Histological typing of tumours of the thymus, in: World Health Organization. International histological classification of tumours. Berlin Heidelberg:Springer, pp1-16.
- Shin, D.M., Walsh, G.L., Komaki, R., Putnam, J.B., Nesbitt, J., Ro, J.Y., Shin, H.J., Ki, K.H., Wimberly, A., Pisters, K.M., Schrupp, D., Gregurich, M.A., Cox, J.D., Roth, J.A. & Hong, W.K. 1998. A multidisciplinary approach to therapy for unresectable malignant thymoma. *Ann Intern Med* **129**: 100-1004.
- Singhal, S., Shrager, J.B., Rosenthal, D.I., LiVolsi, V.A. & Kaiser, L.R. 2003. Comparison of stages I-II thymoma treated by complete resection with or without adjuvant radiation. *Ann Thorac Surg* **76**: 1635-1642.
- Ströbel, P., Bauer, A., Puppe, B., Kraushaar, T., Krein, A., Toyka, K., Gold, R., Semik, M., Kiefer, R., Nix, W., Schalke, B., Müller-Hermelink, H.K. & Marx, A. 2004. Tumor recurrence and survival in patients treated for thymomas and thymic squamous cell carcinomas: A retrospective analysis. *J Clin Oncol* **22**(8): 1501-1509.
- Ströbel, P., Marx, A., Zettl, A. & Müller-Hermelink, H.K. 2005. Thymoma and thymic carcinoma: An update of the WHO classification. *Surg Today* **35**: 805-811.
- Thomas, C.R.Jr., Wright, C.D. & Loehrer, P.J. 1999. Thymoma: State of the Art. *J Clin Oncol* **17**: 2280-2289.
- Venuta, F., Rendina, E.A., Pescarmona, E.O., De Giacomo, T., Vegna, M.L., Fazi, P., Flaishman, I., Guarino, E. & Ricci, C. 1997. Multimodality treatment of thymoma: A prospective study. *Ann Thorac Surg* **64**: 1585-1592.
- Yagi, K., Hirata, T., Fukuse, T., Yokomise, H., Inui, K., Ike, O., Mizuno, H., Aoki, M., Hitomi, S. &

- Wada, H. 1996. Surgical treatment for invasive thymoma, especially when the superior vena cava is invaded. *Ann Thorac Surg* **61**: 521-524.
- Wang, L-S., Huang, M-H., Liu, T-S., Huang, B.S. & Chien, K.Y. 1992. Malignant thymoma. *Cancer* **70**: 443-450.
- Yokoi, K., Miyazawa, N., Mori, K., Saito, Y., Tominaga, K., Imura, G., Shimamura, K., Hirotsu, T. & Kiso, I. 1992. Invasive thymoma with intracaval growth into the right atrium. *Ann Thorac Surg* **53**: 507-509.